

Cardiac Sarcoidosis – An Under-recognized Myocardial Disease



Thomas F. Lüscher
Senior Editor



Rakesh Sharma
Heart Division, Royal Brompton Hospital; NHLI, Imperial College; School of Cardiovascular and Metabolic Medicine & Sciences, King's College, London, UK



Kshama Wechalekar
Department of Nuclear Medicine, Royal Brompton and Harefield Hospitals, London, UK



Vasileios Kouranos
Interstitial Lung Disease Unit, Royal Brompton and Harefield Hospitals; National Heart and Lung Institute, Imperial College, London, UK

Introduction

Sarcoidosis is a multisystemic, chronic inflammatory disorder involving lymph nodes and lungs characterized by a non-caseating, epithelioid cell granulomatous inflammation of affected organs [1]. Cardiac involvement has been reported in 5-30% depending on the diagnostic criteria [2-4]. The exact pathogenesis is not fully understood, however genetically susceptible individuals do develop an inflammatory response to unknown, yet to be identified antigen(s) resulting in granulomatous inflammation and eventually, fibrosis [1]. Cardiac involvement is particularly concerning; it can be associated with severe clinical complications such as life-threatening arrhythmias, heart failure and sudden cardiac death, while other patients remain asymptomatic [5]. Cardiac sarcoidosis (CS) usually presents with extracardiac involvement however, it can be the initial or even isolated manifestations of the disease. The age- and sex-adjusted incidence of systemic sarcoidosis has been estimated to be around 10 per 100,000 person years [6]. In a Japanese population, women appeared to have a higher prevalence of CS, but earlier cohorts in Europe and the United States have shown a male predominance [7-9].

Diagnosis

CS presents with different phenotypes; this often leads to a delayed diagnosis even in patients with extracardiac manifestation due to the low incidence of cardiac involvement, varying clinical symptoms, and the low awareness among physicians. Patients may present with advanced atrioventricular (AV) block, ventricular tachycardia (VT) and heart failure. Isolated CS has also been detected based on histological evidence [4].

Although a cardiac biopsy could provide a definite diagnosis, a negative result can be misleading due to the patchy nature of the disease. Therefore the diagnosis is usually made through an extracardiac biopsy confirming

granuloma together with advanced imaging modalities. A multi-disciplinary team (MDT) approach significantly increases the accuracy of the diagnosis [10]. A first suspicion may arise during a routine ECG or echocardiogram. ECG abnormalities of CS can include conduction abnormalities (mainly AV blockade of any degree, bundle branch blocks, prolongation or fragmentation of the QRS complex or abnormal Q or T waves), atrial arrhythmias and VT. However, the diagnostic sensitivity is low as is that of echocardiography, particularly in early stages of the disease. Mild ventricular wall thickening due to edema or infiltration of the basal interventricular septum or basal inferolateral wall is most typical, but it can be present in any myocardial segment. In more advanced stages, ventricular wall thinning due to myocardial scarring may occur. Thinning of the basal interventricular septum down to four millimeters or less, or regional wall motion abnormalities with non-coronary distribution are quite specific and prognostic [11], if coronary artery disease is unlikely. Speckle tracking may increase the sensitivity [12]. Cardiac MRI and 18-fluorodeoxyglucose positron emission tomography (18-FDG-PET) are widely used imaging modalities [13]. Cardiac MRI detects myocardial structure and tissue alterations, and T1 and T2 mapping can identify myocardial inflammation and myocardial fibrosis based on late gadolinium enhancement [14]. Cardiac 18-FDG-PET is the modality of choice for detecting myocardial inflammation (fig. 1A) and whole body 18-FDG-PET to identify extracardiac sites amenable for biopsy (fig. 1B) [15].

Universal Guidelines

Unfortunately, there are no validated universal guidelines for the diagnosis of CS. Indeed, there are various diagnostic criteria published in the literature (table 1) [16-18]. It is recommended to assess patients in experienced referral centers by established MDTs consisting of cardiologists and respiratory physicians.

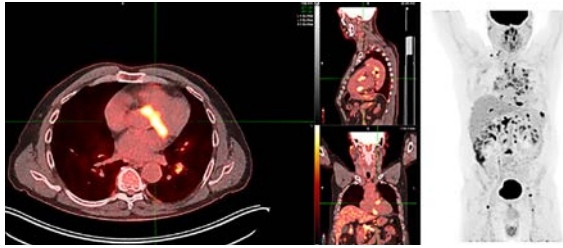


Figure 1A: Focal intense fluorodeoxyglucose uptake in the basal anteroseptal and inferoseptal left ventricular myocardium and mediastinal lymph nodes (left). Overview of FDG uptake in lymph nodes in the neck, chest, upper abdominal, inguinal sites, lung, spleen and L3 vertebra (right).

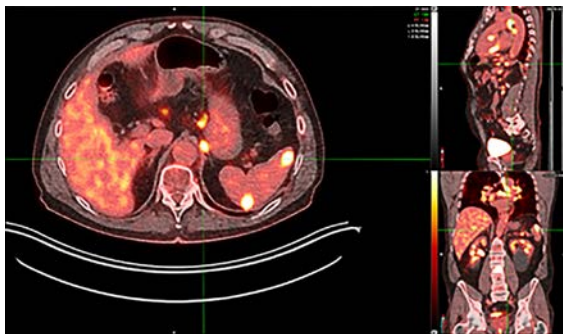


Figure 1B: Extracardiac sites of fluorodeoxyglucose uptake. Mediastinal and bilateral hilar lymph nodes (yellow arrows), splenic foci (blue arrows) and L3 vertebra.

Risk Assessment

CS is a potentially fatal condition that can vary considerably in its clinical presentation; therefore, there is a great need to establish reliable risk predictors of clinical outcomes.

We have investigated potential risk predictors in 319 patients with CS seen at our institution. During a follow-up of up to eleven years, 8% died, while 33% reached the composite endpoint of all-cause mortality, major arrhythmic events, unplanned hospitalization for heart failure or cardiac transplantation. The annualized mortality rate was 2.7% and the 5- and 10-year mortality rates were 6.2 and 7.5%, respectively. Multivariate analysis revealed serum brain natriuretic peptide levels with a hazard ratio (HR) of 2.41, cardiac MRI-based left ventricular ejection fraction (LVEF) with HR 0.96, and maximum standardized uptake value during 18-FDG-PET with HR 1.11 as independent predictors of clinical outcomes [19]. The use of such predictors may be relevant for the long-term care of patients with CS.

Management

Unfortunately, as far as the management of sarcoidosis and in particular its cardiac involvement is concerned, randomized evidence is lacking. However, common practice currently involves anti-inflammatory and, if required, anti-arrhythmic and heart failure treatment [20].

Patients with CS often present with an AV blockade in different degrees; some even with

Table 1: Diagnostic criteria for cardiac sarcoidosis by international cardiological societies

Heart Rhythm Society	Japanese Cardiac Society
Histology: Non-caseating granulomatous myocardial inflammation without infection	
A) Histology of extracardiac sarcoidosis	A) Histology or clinical findings of extracardiac sarcoidosis
B) One or more cardiac manifestations Immunosuppression-responsive CM Immunosuppression-responsive AVB Unexplained LVEF <40% Unexplained sustained, spontaneous or induced VT Advanced AVB (>2nd degree) 18-FDG uptake on PET with CS pattern LGE on CMR with CS pattern 67-Gallium citrate uptake with CS pattern	B) ≥2 major or 1 major and ≥2 minor criteria Major criteria: Reduced LVEF <50% Sustained VT/VF Advanced AVB (>2nd degree) IVS thinning, abnormal LV/RV wall 18-FDG uptake on PET LGE on CMR Positive 67-Gallium citrate scintigraphy Minor criteria: ECG: nsVT, multifocal/frequent PVCs, LBBB, RBBB, axis deviation, Q waves Perfusion defects on MPS Monocyte infiltration EMB: Myocardial interstitial fibrosis
C) Other causes for cardiac manifestations excluded	C) Coronary angiography, CT or CMR to exclude CAD

AVB: Atrioventricular block; CAD: Coronary artery disease; CM: Cardiomyopathy; CMR: Cardiac magnetic resonance imaging; CS: Cardiac sarcoidosis; EMB: Endomyocardial biopsy; FDG: Fluorodeoxyglucose; IVS: Intact ventricular septum; LBBB: Left bundle branch block; LGE: Late gadolinium enhancement; LV: Left ventricular; LVEF: left ventricular ejection fraction; MPS: Myocardial perfusion scan; nsVT: Non-sustained ventricular tachycardia; PET: Positron emission tomography; PVC: Premature ventricular contraction; RBBB: Right bundle branch block; RV: Right ventricular; VF: Ventricular fibrillation; VT: Ventricular tachycardia.

ventricular arrhythmias [18]. Clinical experience suggest that early administration of high dose steroids may reverse high grade AV blockades, though this evidence is based on small non-randomized studies [21]. Atrial and ventricular inflammation interfere with physiological homogenous depolarization of the myocardial tissue and can trigger arrhythmias. Thus, in CS, VT and fibrillation may occur even in the presence of normal AV transmission, first-degree AV block, or normal or only mildly reduced LVEF. Due to the risk of VT, patients with high-degree AV blockade and signs of inflammation and/or fibrosis on imaging should receive an implantable cardioverter defibrillator rather than only a pacemaker. Antiarrhythmic drugs should be used with caution as betablockers can unmask or increase an AV blockade and class I antiarrhythmics can be proarrhythmic. Amiodarone, although effective, has not been investigated in CS and has an unfavorable side effect profile in long-term use. Catheter-based ablation has been used with mixed success and may not be effective during persisting inflammation. Patients with reduced LVEF are managed based on heart failure guidelines irrespective of underlying pathologies [22].

Long-term anti-inflammatory therapy with steroids, second-line immunosuppressive medications (e.g., methotrexate and azathioprine) and, in resistant cases, with tumor necrosis factor alpha (TNF α) antibodies [23–24] is currently used in an individualized manner based on clinical experience and judgement. An ongoing randomized controlled trial in patients with CS is expected to provide more accurate information regarding the role of anti-inflammatory medications for its management [25].

Unmet Medical Needs

In the future, basic research is required to delineate the exact inflammatory pathways involved in sarcoidosis and in particular its cardiac involvement to provide a basis for more specific anti-inflammatory therapies. At the clinical level, large registries should be created to allow for the development of well-established and clinically useful risk scores of clinical outcomes, ideally based on machine learning. Finally, and most important, randomized trials

with different anti-inflammatory regimens should be planned to provide a management based on solid evidence.

Conflict of Interest Statement

All authors have significantly contributed to this editorial. TFL received research and educational grants to the institution from Abbott, Amgen, AstraZeneca, Boehringer-Ingelheim, Dacadoo, Daichi-Sankyo, Menarini Foundation, Novartis, Novo Nordisk, Philips, Pfizer, Roche Diagnostics, Sanofi and Vifor as well as honoraria from Amgen, all outside this work. All other authors have no potential conflicts of interest to declare.



References

You will find the full list of references online at <https://cvm.swisshealthweb.ch/en/article/doi/cvm.2024.1324050930/>.